

DIAGNOSING EFFUSIVE FIP

1. HISTORY: AGE BREED

An opportunity for FCoV infection is essential
 Around 70% of cats with FIP are pedigree
 Any age, but over 50% of cats with FIP are < 2 years old (see table)
 Usually a history of stress within weeks prior to presentation

Likelihood of effusive FIP according to age and breed
 Soma *et al*, 2004.

| Age (yrs) | Pedigree cat | Domestic cat |
|-----------|--------------|--------------|
| <1 | 95 | 79 |
| 1 | 70 | 42 |
| 2-3 | 53 | 41 |
| 4-5 | 60 | 33 |
| 6-7 | 20 | 21 |
| 8-9 | 23 | 34 |
| ≥ 10 | 11 | 14 |

2. CAT PRESENTS WITH ABDOMINAL ENLARGEMENT OR DYSPNOEA

Clinical examination reveals an effusion: which may be abdominal, pleural, pericardial, scrotal
 Cats with effusive FIP are often pyrexic, sometimes anorexic, bright or dull

Sample the effusion

3. IN HOUSE EXAMINATION OF THE FLUID

Pus Blood Urine Appearance Straw coloured, clear, not odiferous, chylous

Protein level <10g/l < 30g/litre >35g/litre

FIP UNLIKELY

Albumin:globulin ratio

> 0.8 Bacteria, malignant cells or mostly lymphocytes Cytology Neutrophils and macrophages

93% unlikely to be FIP Negative Rivalta test Positive PPV 58%

Negative* FCoV antibody test ON BLOOD Positive

FIP UNLIKELY BUT POSSIBLE

FIP UNLIKELY BUT POSSIBLE

4. SEND EFFUSION TO EXTERNAL LABORATORY

Normal rules out FIP (<500µg/ml) AGP Raised (> 1000µg/ml)
 Negative FCoV RT-PCR Positive

FIP POSSIBLE

FIP POSSIBLE

The predictive value of a negative FCoV RT-PCR test on an effusion depends entirely on the sensitivity of the test being used

5. Is FIP

Treat with Mutian; feline interferon omega: 1 MU/kg s/c eod or to site of effusion; meloxicam; Vit B12 injections.
 See FIP treatment page at catvirus.com

* FCoV antibody tests should be preferably performed on a blood sample, rather than an effusion sample, due to the risk of false negative results. Meli *et al* Use test kits with best sensitivity available. Addie *et al* 2016

DIAGNOSING NON-EFFUSIVE FIP

1. HISTORY

An opportunity for FCoV infection is essential (e.g. breeder, rescue shelter or other source of FCoV exposure such as a new kitten)
 Around 70% of cats with FIP are pedigree
 Any age, but over 50% of cats with FIP are < 2 years old
 Usually a history of stress weeks to months prior to presentation (e.g. adoption, boarding cattery, neutering within many weeks in dry FIP)

2. CLINICAL EXAMINATION

Persistent moderate pyrexia > 4 days
 Weight loss / failure to gain weight normally – i.e. stunting
 Dull, lethargic, off colour
 Anorexia
 Intraocular signs (uveitis, keratic precipitates, aqueous flare, retinal vessel cuffing)
 Neurological signs (ataxia, fits, nystagmus)
 Enlarged mesenteric lymph node(s)
 Icterus
 Enlarged kidneys

Blood sample

3. BLOOD TESTS

| | |
|-----------------------------|-------------------|
| Albumin:globulin | < 0.4 |
| Globulin | Hyperglob >46 g/l |
| Bilirubin | Raised |
| Haematocrit | <30% |
| Anaemia | Non-regenerative |
| Lymphocyte count | Lymphopenia |
| FCoV antibody test** | Positive |

**NOT
FIP**

**FIP
UNLIKELY**

**NOT
FIP**

4. EXTERNAL LABORATORY

Normal **ALPHA-1 ACID GLYCOPROTEIN** Above 1500 ug/ml
 Negative **SEND MLN FNA / BIOPSY/ AQUEOUS HUMOUR FOR RT-PCR** Positive

**FIP
POSSIBLE**

The predictive value of a negative FCoV RT-PCR test depends on the sensitivity of the test being used, the integrity of the RNA during mailing, and that an FIP lesion was accurately selected. **DO NOT DO RT-PCR ON SERUM OR BLOOD** – the test will be negative even in cats with FIP

IS FIP - TREAT

Mutian; 100,000 units of feline interferon omega per os sid plus meloxicam; Vit B12 injections. May add Polyprenyl immunostimulant.
 See treatment section of catvirus.com

* Note that 15% of cats with FIP have alb:glob 0.8
 ** Use test kits with best sensitivity available. Addie et al 2016

Diagnosing FCoV associated enteritis

HISTORY: AGE BREED
An opportunity for FCoV infection is essential, e.g. cattery exposure
Any age of cat, though kittens over-represented, especially purebred
History of diarrhoea, plus or minus vomiting
No nutritional explanations, e.g. giving cow's milk

CLINICAL EXAMINATION
Possible stunting or weight loss
Possible third eyelid protrusion
Gassy abdomen possible
Thickened large intestine possible
Enlarged mesenteric lymph nodes

NOT FCoV ENTERITIS

Blood sample

BLOOD TESTS
FCoV antibody test
Negative* Positive
Check other parameters to see if FIP is a concern
(see non-effusive FIP algorithm)

FCoV ENTERITIS UNLIKELY:
depends on sensitivity of test used

FCoV ENTERITIS POSSIBLE

FAECAL SAMPLE
FCoV RT-PCR

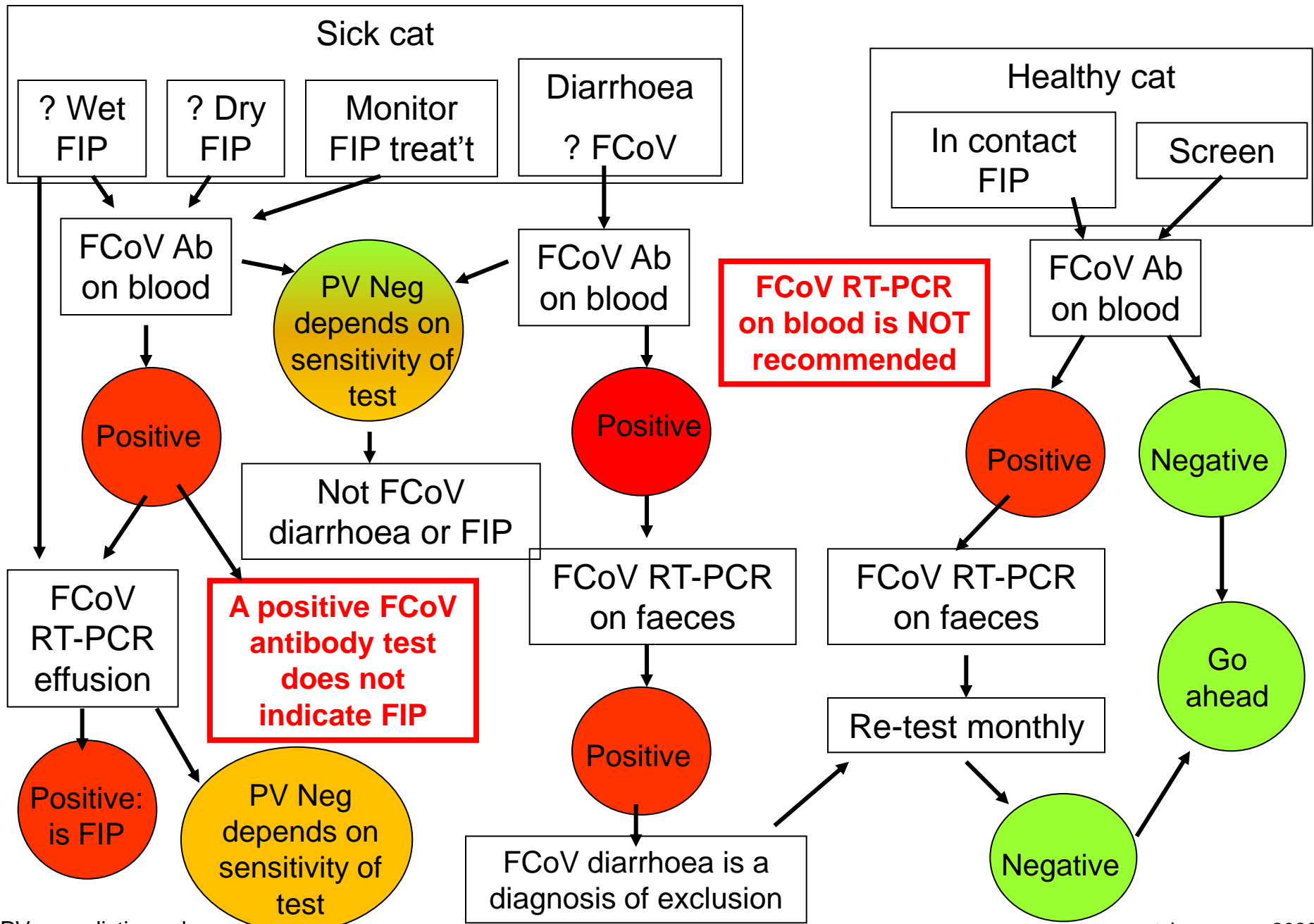
Negative

Positive

Be sure to rule out other bacterial, viral, protozoal, nutritional and parasitic causes

IS FCoV ENTERITIS
Treat with Mutian; feline interferon omega and Protexin Pro-Kolin Enterogenic probiotics

USING FCoV ANTIBODY AND RT-PCR TESTS



PV = predictive value